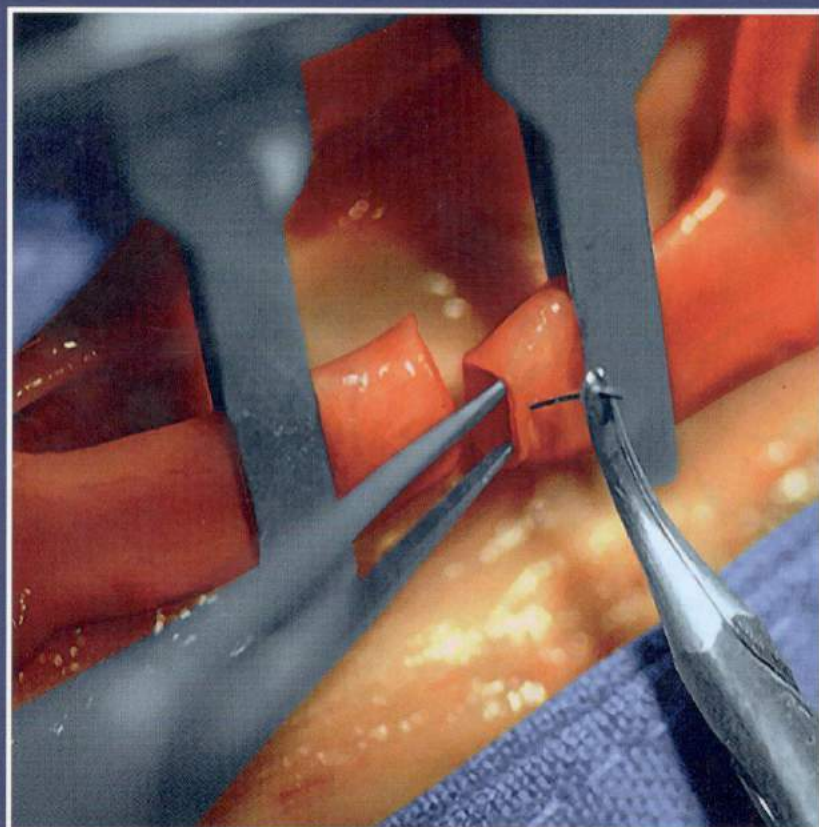



M. Bumbaširević
A. Georgescu
P. N. Soucacos

Technical Tips & Tricks for Reconstructive Microsurgery **HOW I DO IT**



14th Congress of the European Federation
of Societies for Microsurgery

Belgrade, May 5 – 8, 2018



ЗАВОД ЗА УЏБЕНИКЕ

M. BUMBAŠIREVIĆ, MD, PHD
A. GEORGESCU, MD, PHD
P. N. SOUCACOS, MD, FACS

Technical Tips & Tricks for Reconstructive Microsurgery HOW I DO IT



Zavod za udžbenike • Beograd

Technical tips in distal finger replantations

16

**Fatih KABAKAŞ¹, Bülent ÖZÇELİK¹, Berkan MERSA¹, İlker Sezer¹,
Hüsrev Pürisa¹, İbrahim Alper Akasakal¹, Taçkın ÖZALP²**

¹IST-EL Hand Surgery, Microsurgery and Rehabilitation Group, Istanbul, Turkey

²Department of Orthopaedics and Trauma Surgery, Celal Bayar University,
Manisa, Turkey

Distal finger replantation is a challenge in microsurgery. Replantations distal to the flexor digitorum superficialis were initially termed as distal finger replantations [1] but today what is meant by a distal replantation is replantation through or distal to the distal interphalangeal joint [2].

Although controversy exists for the benefits of distal finger replantations, the results are superior to stump revision and other reconstruction methods both func-

tionally and cosmetically. The main advantages of distal finger replantation may be summarized as: it is a single stage procedure providing a good soft tissue coverage, good sensibility without painful neuroma, good range of motion in the affected joints, preservation of nail and finger length, cosmetically pleasing and satisfying the patient [3]. Longer operation times, longer hospital stays, longer time off work, and higher costs are main drawbacks of this operation [4].

Technical difficulties are another important drawback. The vessel sizes are so small that needs patience and skill for repair. Vessel diameters range between 0.8 to 0.3 mm [5,6]. It's difficult to find and tag these small vessels for repair. These fragile, thin vessels need delicate manipulation and have no tolerance to tightness in repair. Moreover, a good exposure and a comfortable space are needed to perform the fine anastomoses which is usually not the situation. Experience is so important for a successful result. However, there are problems in transmission of experience. Replantation is an emergency surgery and learned in the operating rooms after long hours and generally without supervision of senior surgeons. Every new resident has to experience the technical difficulties and find his way to solve the problems [2].

Depending on experience every surgeon has his own technical problems and his original solutions for the peculiar problems.

The aim of this chapter is to present our solutions and technical tips while performing distal finger replantation.

Management in the emergency room

Digital block anesthesia in the emergency room will relieve the patient and if performed with a long acting bupivacaine this can last until the end of operation. We usually perform distal finger replantations with local anesthesia and find it safe. This will help both the patient and the surgeon while inspecting the injury and informing the patients about the operation and possible outcomes (*Figure 1a*).

The X-rays of the amputated part and stump also photographs of the amputated part and stump should be taken at emergency, this will

help in planning the surgery and will give idea about bone and joint condition. Infrequently there may be a more distal or proximal fracture and foreign bodies may be detected (*Figure 1b*).

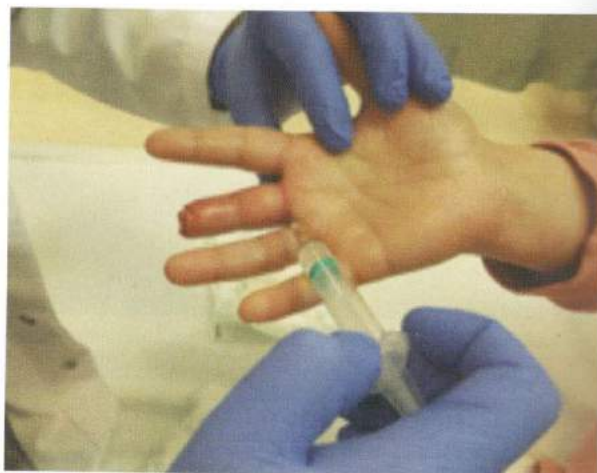

Figure 1: a) Digital block anesthesia.

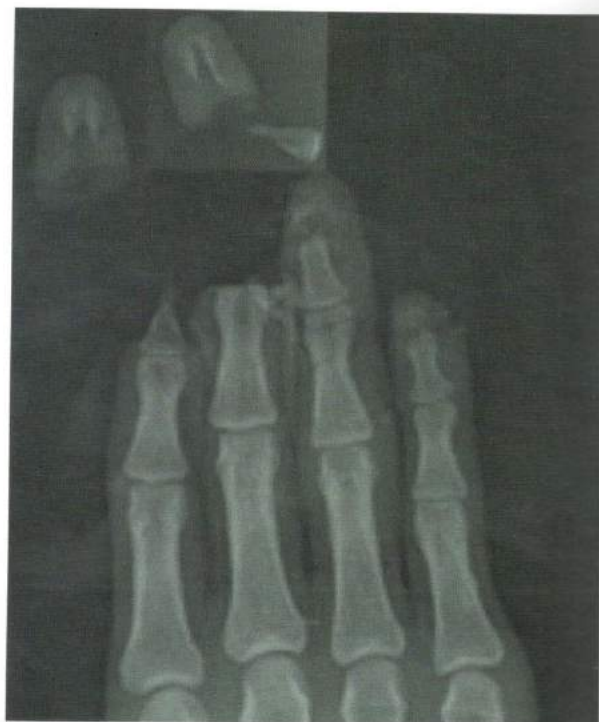

Figure 1: b) Fractures within the amputated segments

Preparation to replantation

If a decision is made to replantation with an informed consent of the patient than the surgeon should carry the amputated part

to the operation room by himself without waiting (Figure 2).

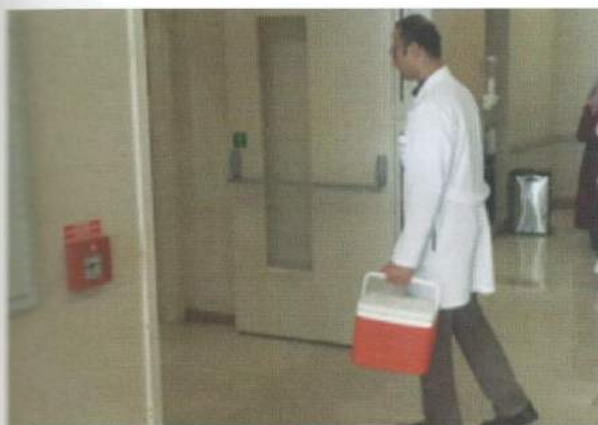

Figure 2: The amputated segment is carried by the surgeon.

This will save time. While the patient's paperwork and preparation for operation is performed, in emergency room the surgeon will be in the operating room preparing and tagging the amputated part. Most importantly this manoeuvre will prevent loss of amputated parts during transport (Figure 3).

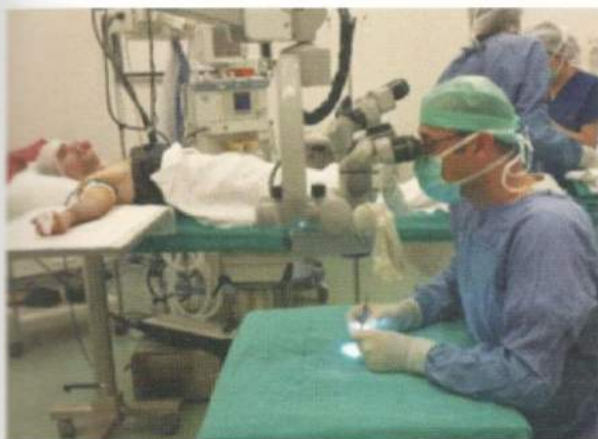

Figure 3: While the patient is taken to operating room and prepared for the operation, the surgeon will be already finishing with preparation and tagging of the amputated part.

Patient considerations

We should keep in mind that; patient's comfort during operation equals surgeon's

comfort. The patient should go to toilet before operation because not rarely the patients need urination during the critical moments of the operation and we do not want to use urinary catheters. The operation room must be heated for optimal vasodilation and comfort of the patient.

The silicone headpieces used during general anesthesia is uncomfortable for the locally anesthetized patient. We use a normal pillow as used in the patient's room during operation (Figure 4).

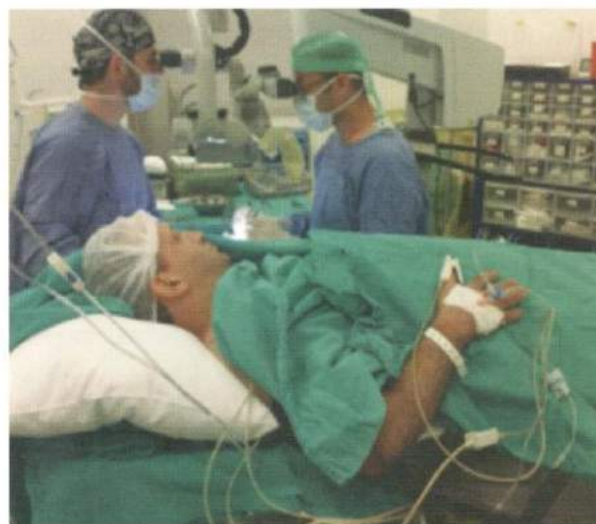

Figure 4: Established comfort of patient during replantation.

The intravenous lines (IV) should be settled at the dorsum of the contralateral hand not in the cubital area. Patients frequently comply about cubital IV lines during operation because they cannot move elbow due to pain. Our emergency team is informed about this matter and the IV line for finger amputation patient is settled on the contralateral hand dorsum at the initial preparation in emergency room (Figure 4).

Sometimes sedation is needed for patient's or surgeon's comfort but this may cause involuntary movements that can be detrimental during fine anastomosis.

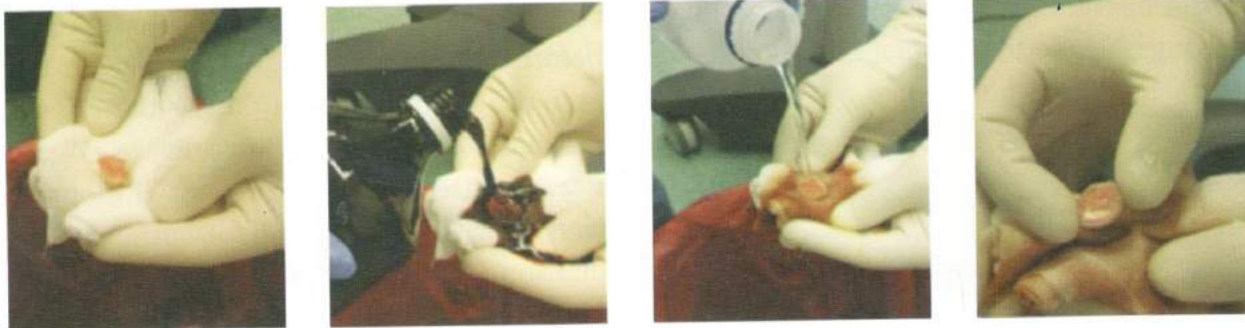

Figure 5: a) Holding without squeezing. b) Use of betadine. c) Saline wash. d) Manipulation

Preparation of the amputated finger

The amputated part should be prepared without squeezing to keep the blood within. That will help in detection of vessels especially small volar veins.

Betadine instead of foaming scrubs should be used. Because detergents in the scrubs permeate to connective tissues and vascular lumens which takes time to clean out. The betadine should be washed generously with saline. If needed the amputated part should be manipulated by holding from the lateral parts of nail not to squeeze and lose the blood of the pulp (*Figure 5*).

Stabilizing the finger for debridement and tagging

Stabilizing the amputated finger for debridement and tagging is usually performed by an assistant who holds the finger. The problem is tremor of the assistant during tagging. Few techniques are defined to overcome this problem in the literature. Defined techniques in the literature for stabilizing the amputated segment include: using hypodermic needles and a cork board, stay sutures attached to the operating table [7], using silicone finger mat of microsurgical instrument tray [8] and suturing the amputated part to a suture pack [9].

What we use for stabilization is a forceps (*Figure 6*). The microvascular clamp applicator forceps is suitable for stabilization [10].

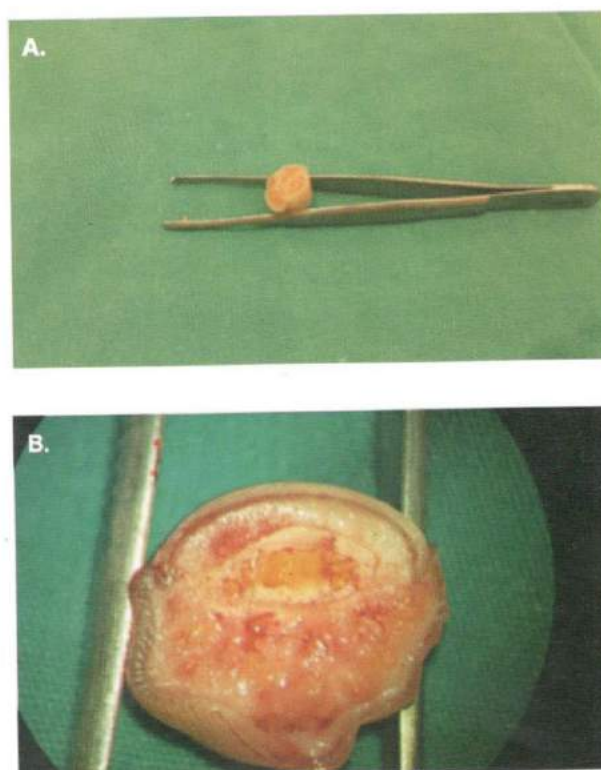


Figure 6: a) Use of forceps for stabilization. b) View of whole cross section

There is no assistant and no tremor. It fixes for easy debridement and tagging. Exploring the whole cross-section provides a better look in order to find and compare the available vessels.

Compression of the pulp will push the blood to the vessel ends and will make it easy to locate and tag (*Figure 6c*).

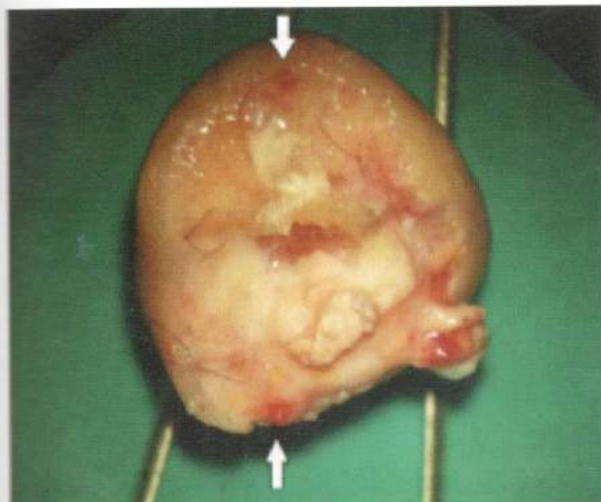


Figure 6c: Arrows indicate visible volar and dorsal veins with compression of the pulp

Debridement

The amputated part may be contaminated with oily grease, small metal particles, or soil (*Figure 7*). Debridement is needed in these situations but one can lose valuable vessel

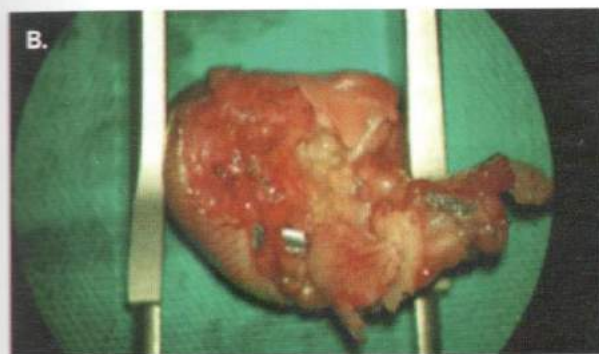
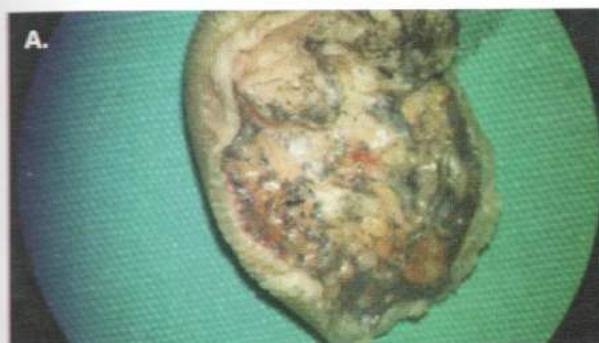

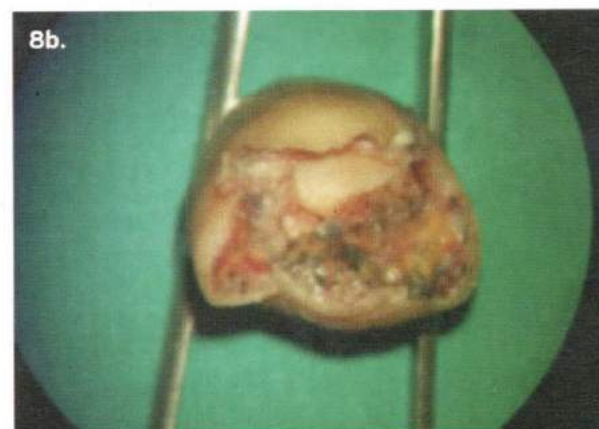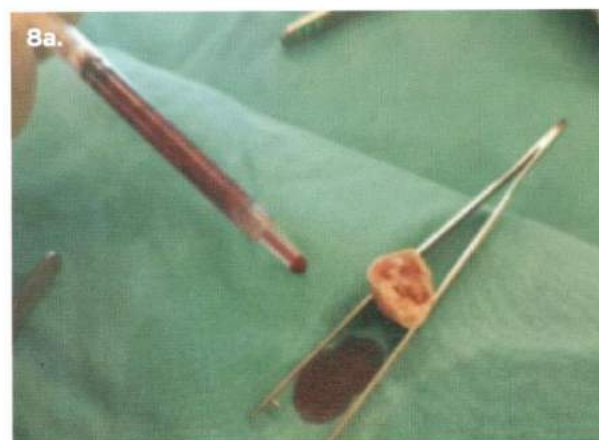Figure 7: a) Contamination with grease. b) Metal foreign bodies

length during non-discriminant debridement. Neuro vascular structures should be explored before debridement and protected. A magnet located in a sterile glove finger may be used to collect the iron metal particles. Depending on the power of the magnet superficial free big iron particles can be collected by this method but the small ones within the tissue will still take time of the surgeon.

Staining with blood

After debridement everything is white without contrast under powerful microscope lights which makes it difficult to localize vessels and nerves.

We use a drop of patient's blood obtained from IV line or proximal stump to stain the cross-section (*Figure 8*).



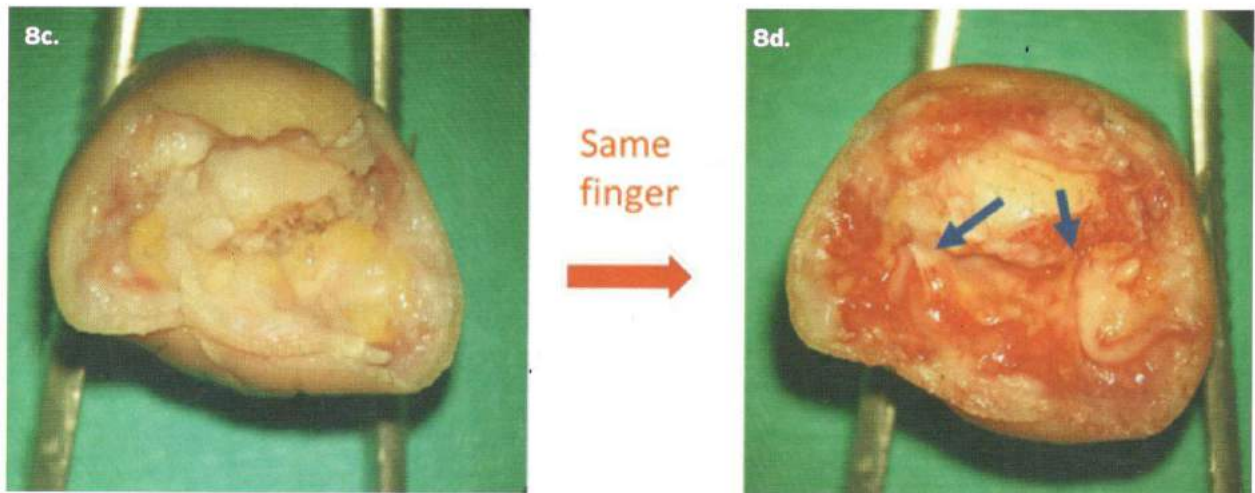


Figure 8: a) Staining with a drop of blood. b) Amputated part before debridement. c) The same finger after debridement. d) Same finger after staining with a drop of blood. Arrow indicated the neurovascular structures made visible.

Staining with a drop of blood puts a base colour that enables surgeon to see the transparent neurovascular structures (Figure 9). Moreover, the blood nestles within and around vessels that makes it easy to locate.

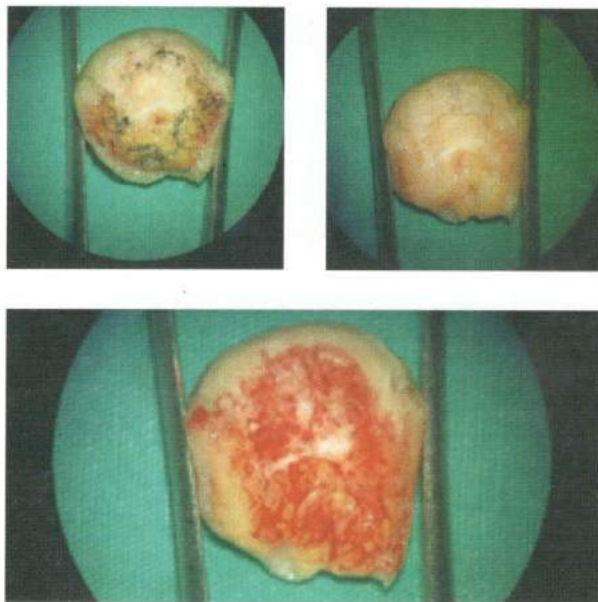


Figure 9: a) Before debridement b) After debridement c) After staining with blood

Tagging

Tagging with sutures is the classical and familiar method however it takes time (Figure 10).

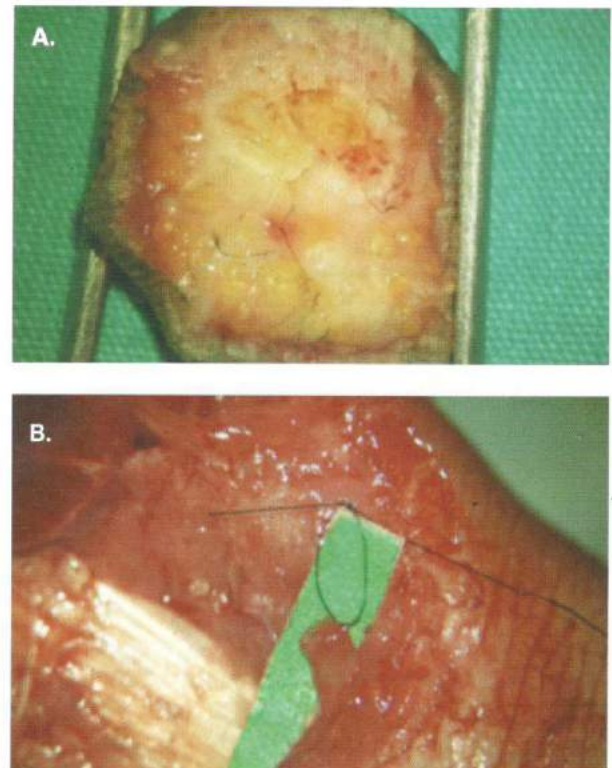


Figure 10: a) Volar veins and arteries tagged. b) Tagging with Loop suture

Loop sutures passing from adventitia may be used if the vessel will be tagged after preparation. The loop is then cut and the suture maybe taken without damaging the vessel.

Tagging with hemoclip is another choice that enables fast tagging. Hemoclip pro-

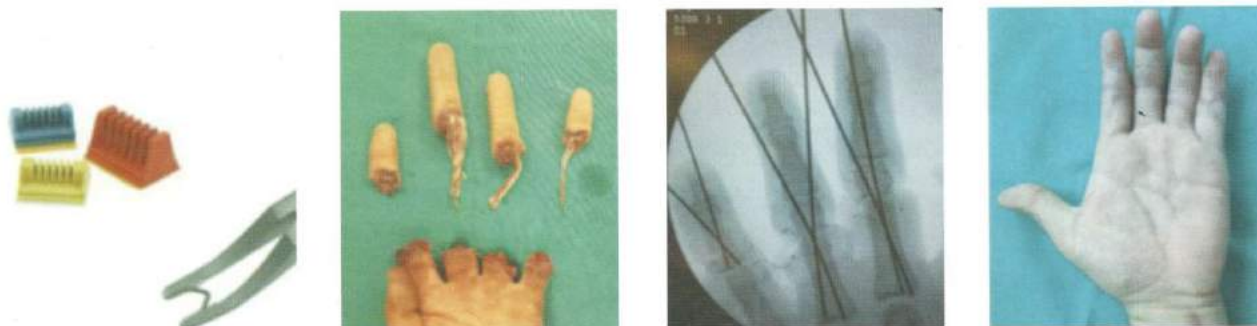

Figure 11: An example in a non-distal multi-finger amputation. Smaller sizes can be used in distal finger replantations.

vides a holding site to manipulate safely. Different sizes may be used for artery, vein and nerve. It decreases bleeding from the stump arteries. It is especially important in multiple finger replantations to save time and decrease bleeding (*Figure 11*). The disadvantages are; it shortens valuable length of the vessel since you have to cut it away

with a part of vessel. Surgeon must not hurry up to cut crushed vessel ends. The lumen may be explored by partial proximal cuts with preservation of the distal crushed segment (*Figure 12*).

Tagging by ligating a proximal injured branch will save time and decrease bleeding (*Figure 13*).

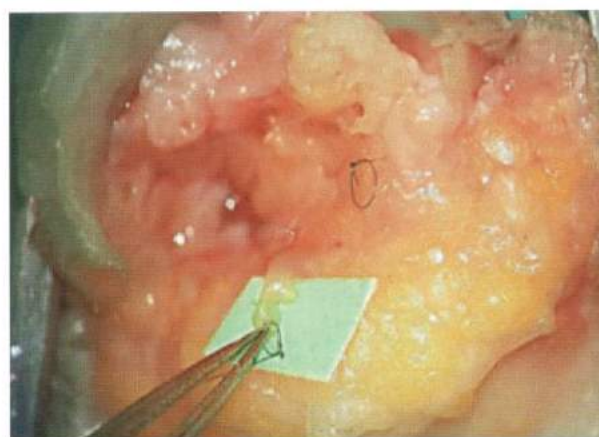
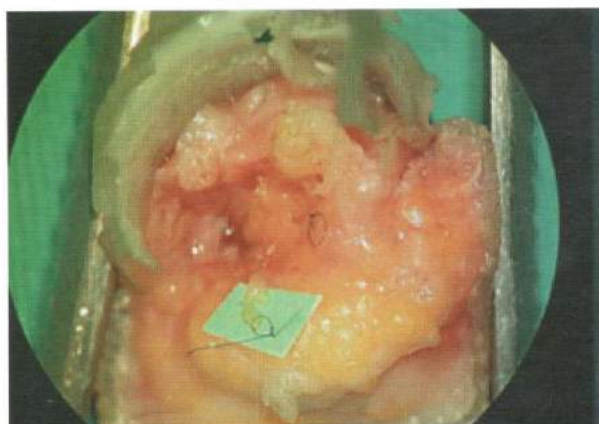

Figure 12: The crushed vessel ends provide safe tagging and holding sites for the surgeon

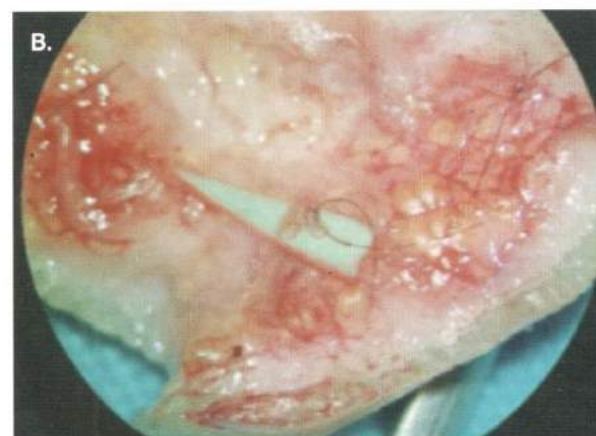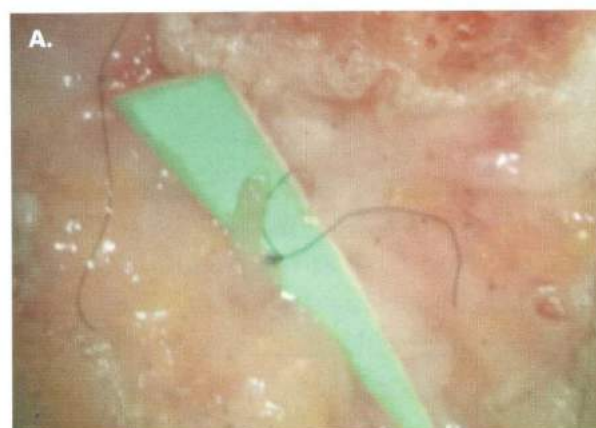


Figure 13 a, b: Two different cases with tagging by ligating an injured branch.

Preperation of the stump

The stump is usually left to stop bleeding by itself with loosely compressive gauzes.

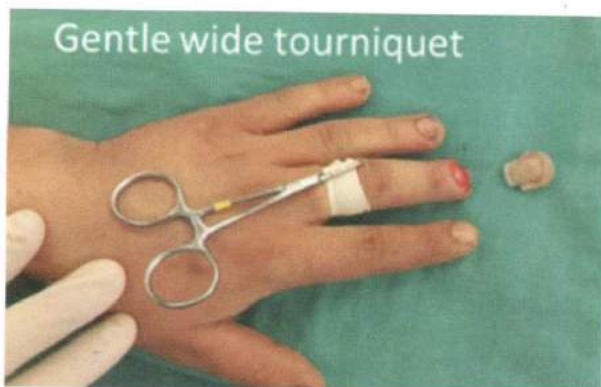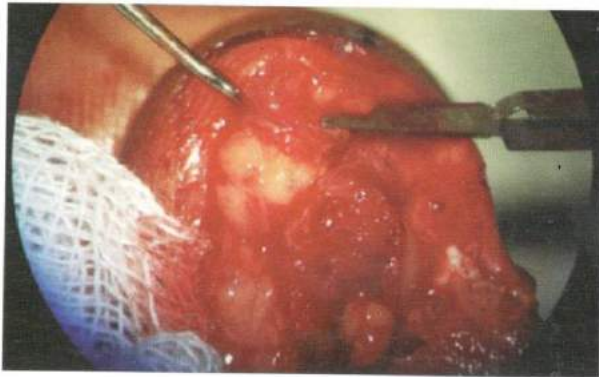


Figure 14: a) Microvascular clamp to stop bleeding. b) Finger tourniquet

The surgeon should stop bleeding from the stump. If it stops by itself then it stops with thrombosis and vasospasm that will complicate the anastomosis. We use microvascular clamps, gentle wide finger tourniquets, and hemoclips to stop bleeding from the stump (Figure 14).

These should be kept in place during bony fixation (Figure 15).

Bony fixation

One must remember that the biggest vein of finger is the medullary cavity of the bone. Complete anatomic reduction is

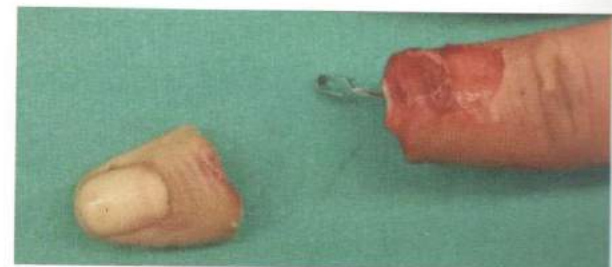
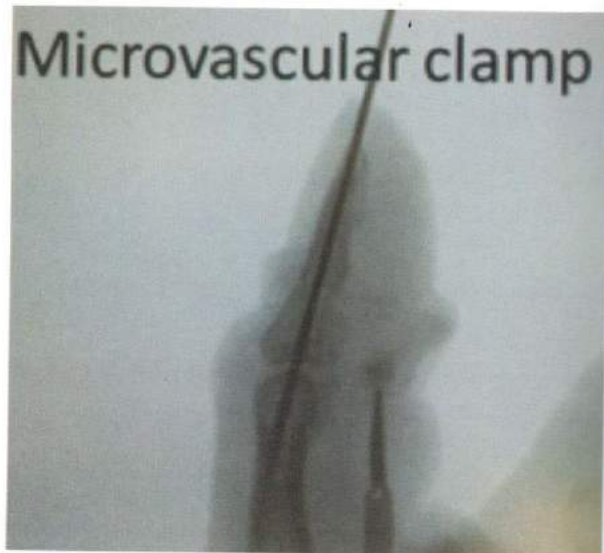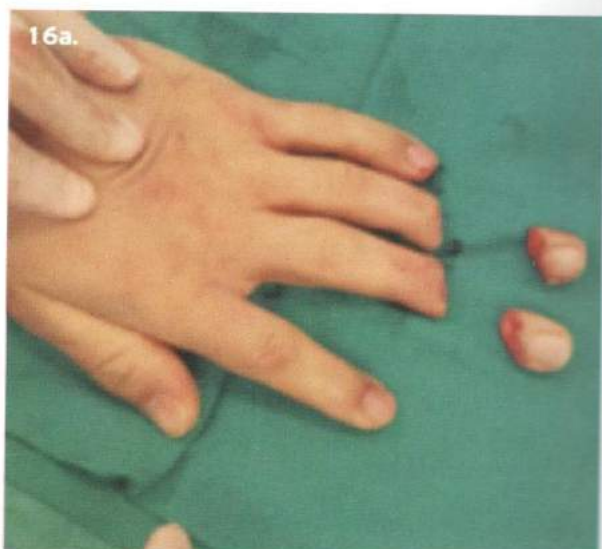


Figure 15: Microvascular clamps should be kept until arterial repair.

needed. It is especially important in distal replantations without vein repair. We try to perform complete anatomic reduction with 0.6 mm to 1 mm K-wire fixation not to occlude the medullary cavity (Figure 16).



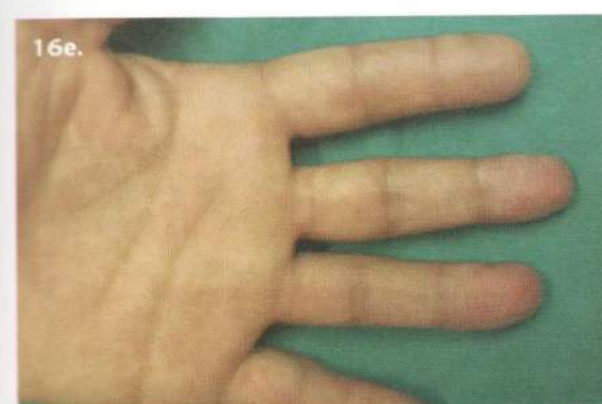
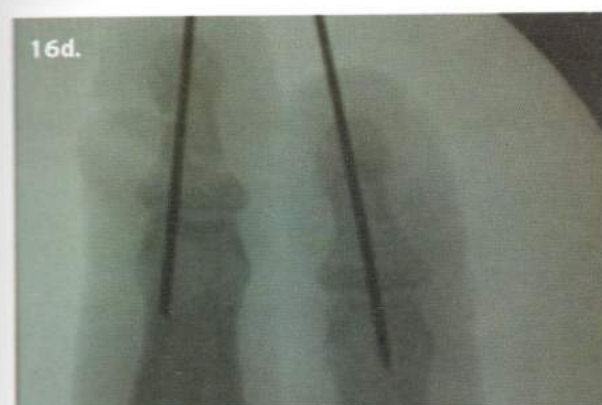
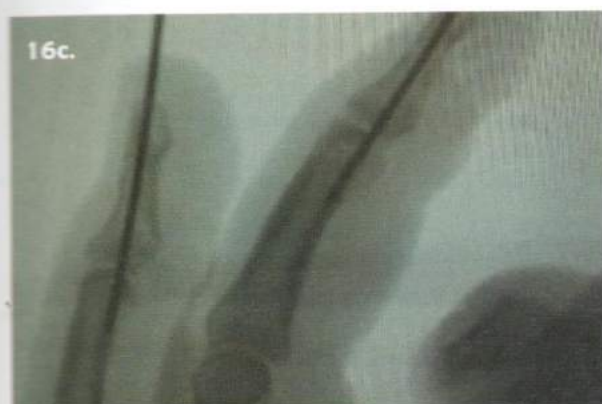
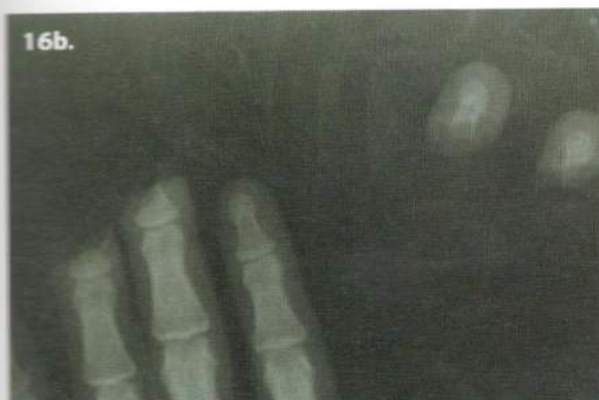Figure 16 a, b, c, d, e: complete anatomic bone reduction obtained in a distal multi-finger amputation.

Radiolucent hand table

We always check the reduction with fluoroscopy for each case. Radiolucent hand table helps for this (Figure 17).



Figure 17: Radiolucent hand table is made of Plexiglas on a steel skeleton. It is cheap and helpful.

Aspiration tube to protect soft tissues

Protection of soft tissues and neurovascular structures during K-wire application is of paramount importance in distal finger replantations. If K-wire catches the vessels, you will lose valuable vessel length that even may not be reconstructed with vein grafts.

We use a segment of aspiration tube as a trocar to K-wire to protect soft tissues (Figure 18).



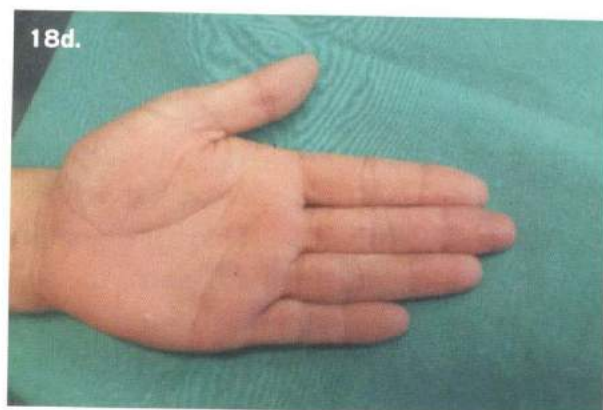
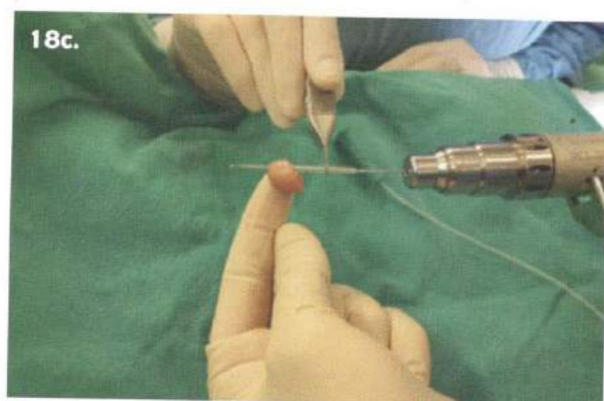
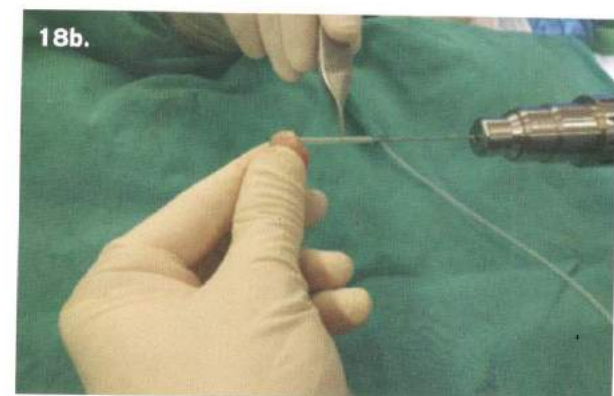


Figure 18: a) A segment of aspiration tube is prepared. b, c) The aspiration tube segment is fixed with a forceps and the K-wire is safely applied. d) Postoperative view of the patient

Tendon repairs

It is usually not needed in distal finger replantations but may be needed in amputations through DIP joint. The extensor tendon repair should not disturb the vein

repairs. Bulging of repair site and suture itself may compress the valuable dorsal vein. The repaired vein is found just between the tendon and skin and vulnerable to compression. We use a running or cross stitches suture by keeping the knot inside to protect valuable vein repair (Figure 19).

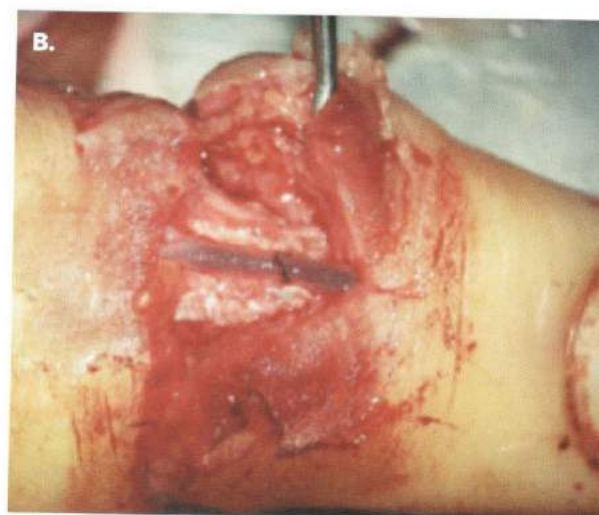
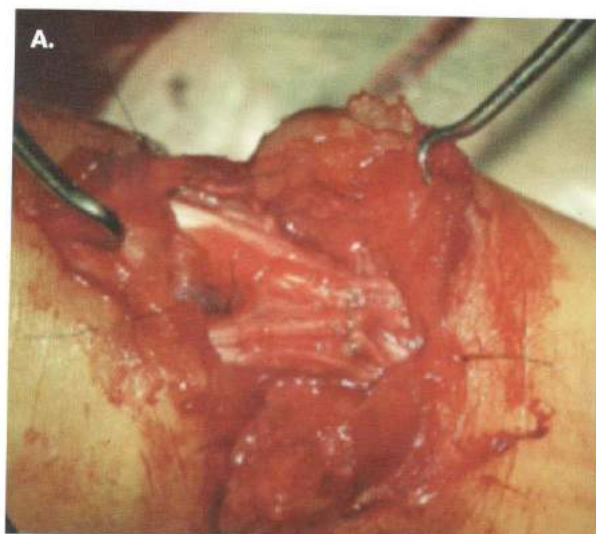
Figure 19: a) Extensor tendon repair without bulging. b) See how the valuable vein repair lies just over the tendon repair site.

Nerve repair

Nerve repairs should be performed in distal finger replantations if possible. However, nerve repair is not an essential repair that must be

performed in all distal finger replantations because protective sensation returns irrespective to nerve repair status. This was confirmed by many studies presenting good sensory recovery without nerve repair in distal finger replantations [11, 12, 13].

If bleeding from the stump artery is good and no dissection will be performed for artery then we do not do proximal exploration just for nerve in avulsion injuries because the spontaneous innervation is satisfactory without nerve repair in distal replantations (Figure 20).

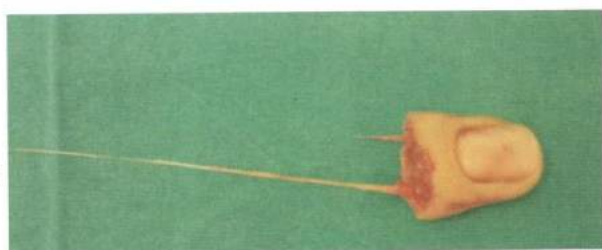


Figure 20: Avulsion injuries

Vascular repairs 12x oculars

We use 12.5x ocular instead of standard 10x oculars 12.5x ocular provides 20% extra magnification which is especially important in distal replantations. One have to increase light at these magnifications (Figure 21).

Dorsal approach for vascular repairs

Distal finger replantations have distinct technical difficulties. The vessel sizes are about 0.8 mm to 0.3 mm [5, 6]. The vessels are thin walled and their flexibility is less compared to proximal replantations. 11/0 sutures are needed in most cases. Tension is not tolerated by this very thin vessels during repair. The bulk of the pulp tissue precludes a wide view of the repair site. Retraction of skin and pulp tissue increases tension on the anastomosis. It is difficult

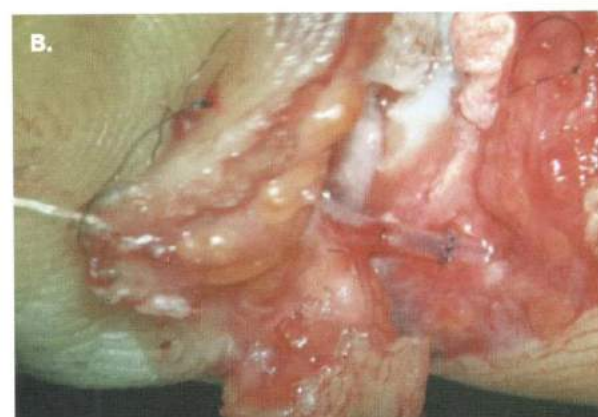
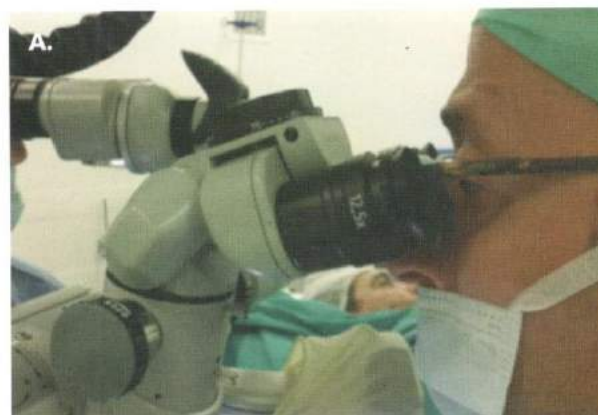
Figure 21: a) 12.5x ocular to increase magnification. b) The quality of repairs increase with extra magnification.

to use microvascular clamps in this narrow field of vision. The artery is in the deepest location just over the periosteum. Classically distal finger replantations are performed by volar approach. We use dorsal approach to overcome some of these technical difficulties. In dorsal approach the vascular repairs are performed from dorsal side before bone fixation [14] (Figure 22).

After preparing and tagging the vessels and nerves of the amputated part and proximal stump, the hand is positioned by lead hand in supine position and the uninjured fingers are fixed with lead hand (Figures 22a, 22b). A K-wire is passed to the amputated part only. The volar skin is repaired first as a hinge and the exposure is obtained from dorsal side (Figure 22b). The exposure is wide enough to

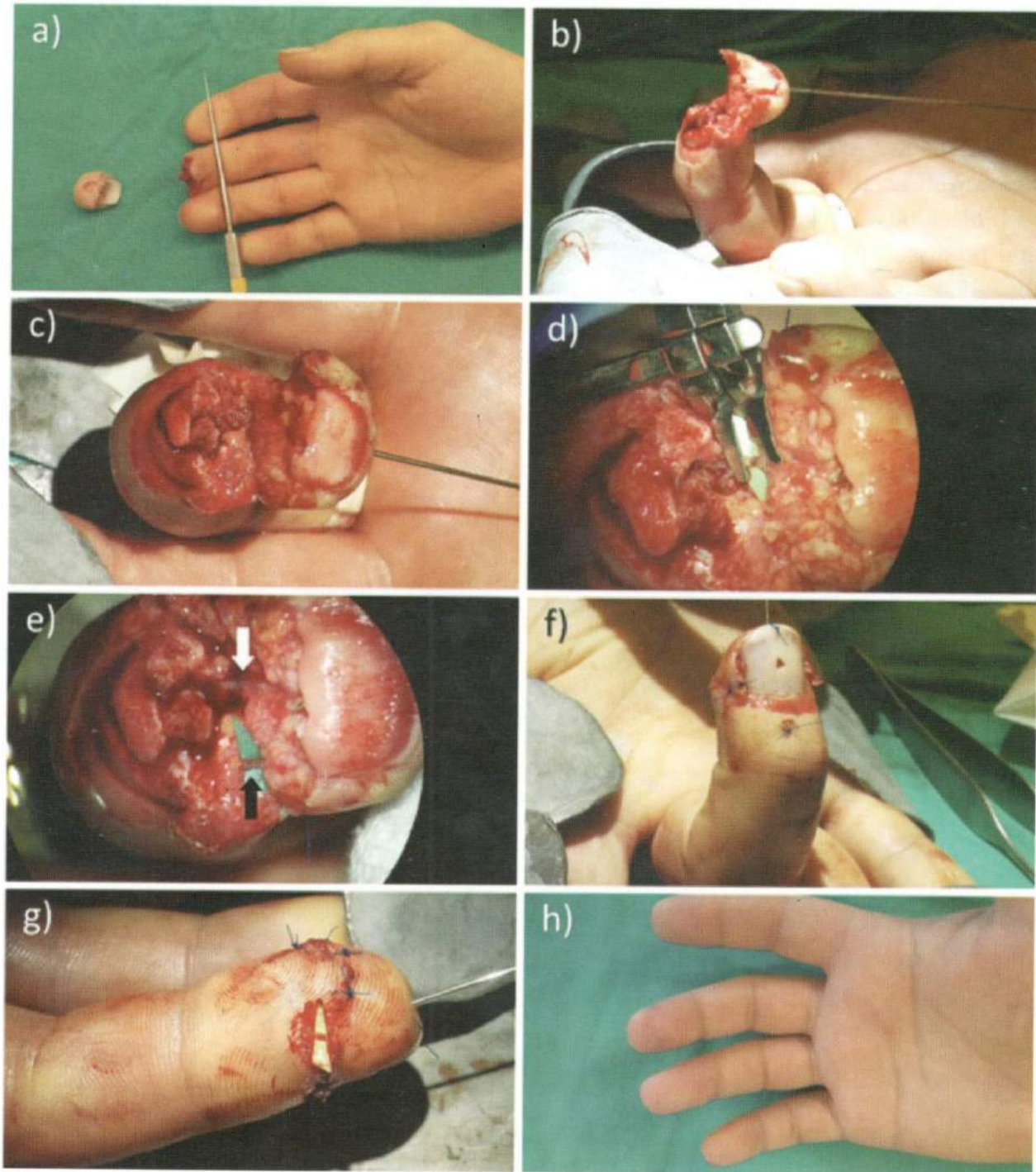
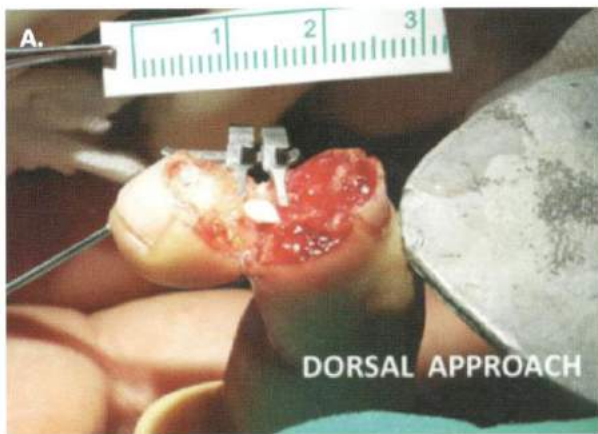

Figure 22: a) A 37-year-old male patient had a transverse Tamai Zone I amputation of the middle finger. The vessels were tagged and prepared. (b) K- wire was passed from the amputated part. Volar skin was repaired without bone fixation. The K wire's length and skin sutures were adjusted to obtain the best exposure with least tension and the amputated part was retracted to volar side using the volar skin as a hinge. The weight of the K-wire stabilized the exposure. (c) Wide exposure of the anastomosis sites was obtained. (d) The exposure was wide enough to place a microvascular clamp if needed. (e) The arterial repair was completed (white arrow). A subcutaneous volar vein was repaired without the need for a microvascular clamp (black arrow). (f) The bone was fixed and lateral skin and nail bed repair was performed and nail plate was fixed with sutures. (g) A previously tagged subdermal volar vein was repaired lastly from volar side. (h) The result at six month.

use microvascular clamp and approximator (Figures 22c, 22d). The structures are repaired from volar to dorsal before bone fixation. As the repairs come dorsally the number of volar skin sutures are increased or the K- wire is manipulated to obtain the best exposure with least tension. Subcutaneous volar veins repaired by dorsal approach (Figure 22e). After completing the repairs by dorsal approach the amputated segment is reduced carefully and the K- wire is passed to proximal bone. Lat-



Volar approach to the same finger

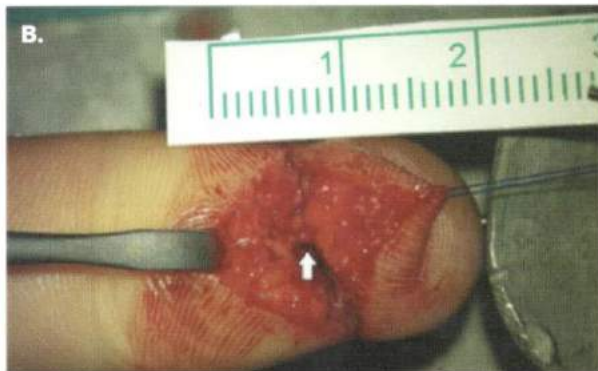

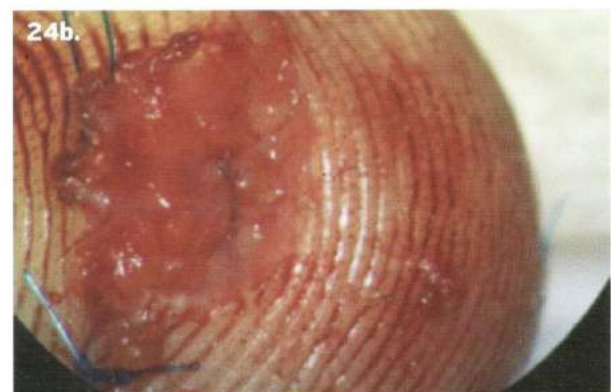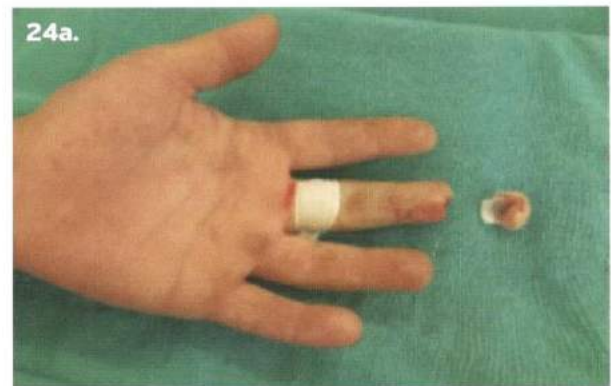Figure 23: a) The exposure of arterial repair in dorsal approach is about 2 cm without need for an assistant to retract soft tissues or without stay sutures. The cross section of cleft for vascular repairs in dorsal approach is like a semicircle providing a better exposure without soft tissue interruption. b) The volar approach to the same finger's arterial repair site (white arrow) results in a 1 cm exposure with the cross section being like a "V". The artery must be repaired at the narrowest bottom of the "V". Moreover, stay sutures and retraction of soft tissues by an assistant were needed to maintain exposure in volar approach.

eral skin and nail bed repair is performed and nail plate is fixed with sutures (Figure 22f). If a previously tagged subdermal volar vein will be repaired than the sutures are taken from the volar skin and the subdermal volar vein is repaired from volar side (Figures 22 g, 22 h).

Using dorsal approach has many advantages over volar approach [14]. Dorsal approach provides 2 times wider exposure compared to volar approach to same finger. There is no need to an assistant or stay sutures. It provides wider space for approximator compared to volar approach (Figure 23).

Vein repairs

The arterial fill must be balanced by venous drainage for a successful result. We routinely perform volar vein repairs [15]. Repairing volar veins is especially important in Tamai Zone I where dorsal veins do not exist (Figure 24).



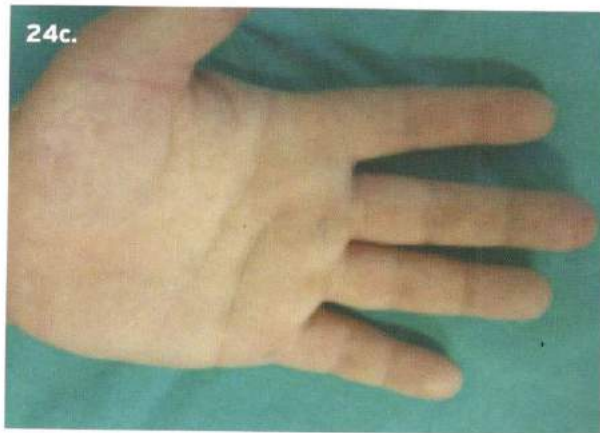


Figure 24: a) Volar veins can be found in subdermal area as in this patient. b) Two neighboring subdermal volar veins were repaired. c) View at sixth month

We frequently repair subcutaneous volar veins in distal finger replantations that are bigger than subdermal ones (*Figure 25*).

Volar veins can be located easily within the microhematomas in the subcutaneous tissue or subdermal area (*Figure 26*).

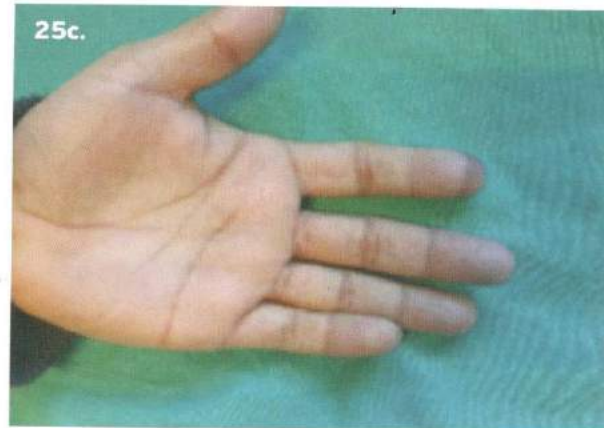
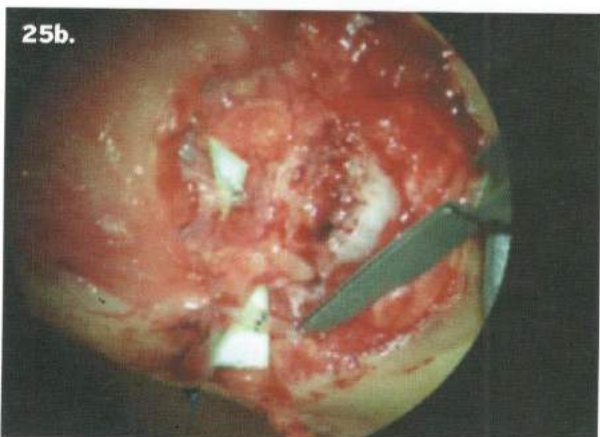
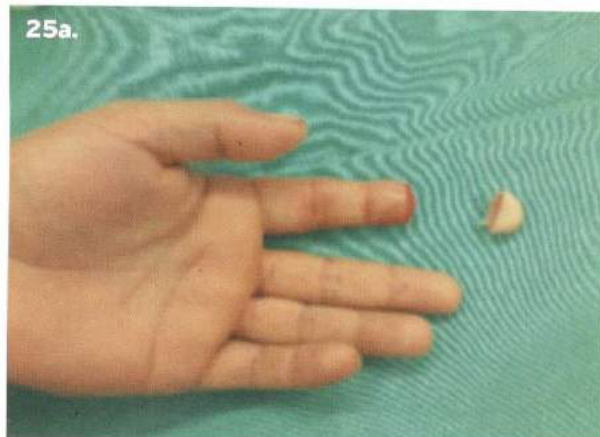Figure 25: a) Second finger amputation. b) One subcutaneous volar vein lateral to central artery is repaired by dorsal approach in this patient. c) View at fourth month

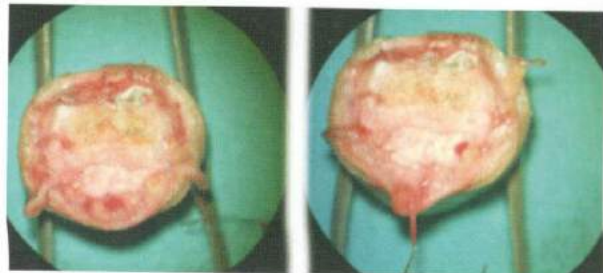


Figure 26: a) The microhematoma at the volar subcutaneous tissue. b) One subcutaneous volar vein was located within the microhematoma.

We frequently repair big volar veins within the subcutaneous tissue of pulp (*Figure 27*).

Skin closure

We always start skin closure from the vascular repair sites first. Because due to edema if we leave it to the last then the anastomosis tend to protrude from the repair site and it is possible to pass sutures from the repaired vessels (*Figure 28*).

Multiple finger

In multiple finger replantations time is important. We sometimes perform the vas-

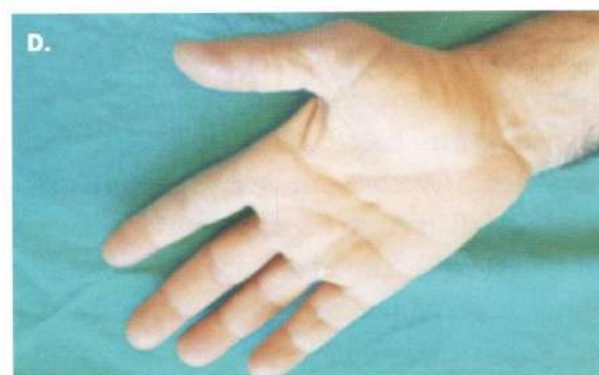
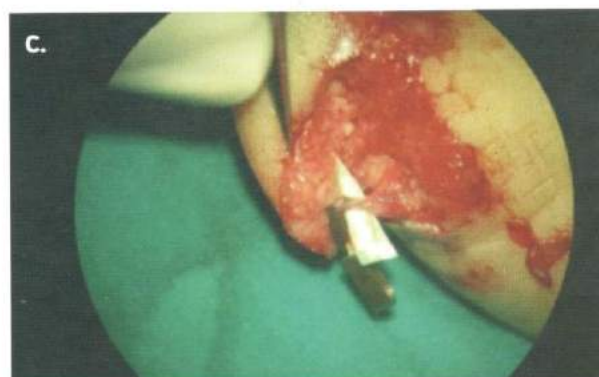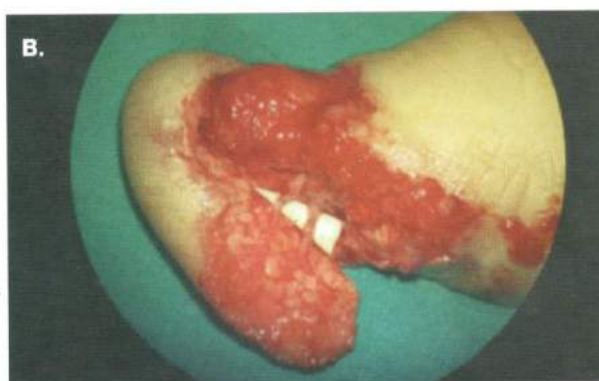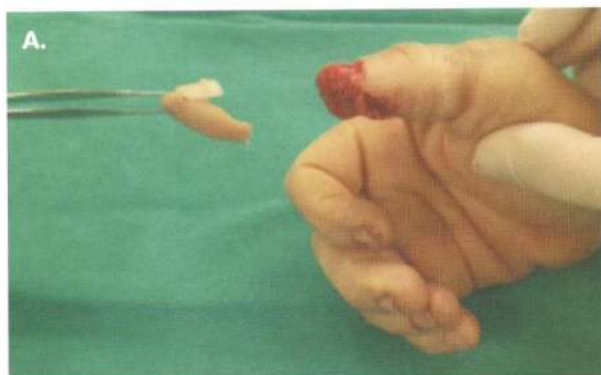


Figure 27: a) Pulp amputation in a 47 years old male. b) Two arteries were repaired c) One big subcutaneous vein repair was enough to balance the arterial fill. d) View at seventh month

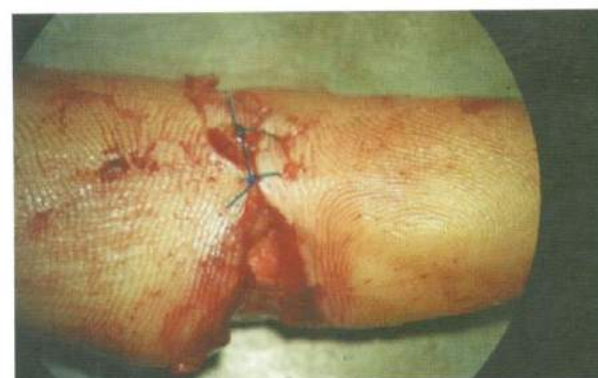
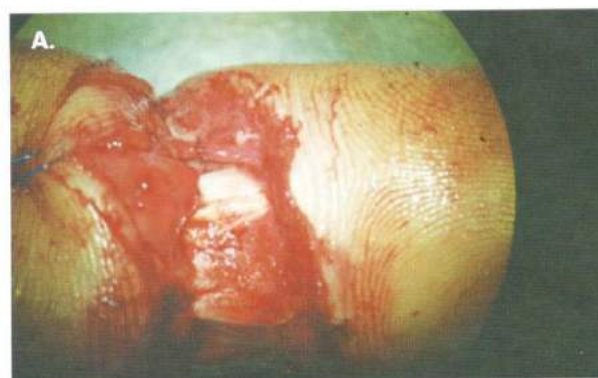
Figure 28: a) Repaired artery in a distal finger replantation. b) Skin closure was started from the repair site first to protect the anastomosis

cular repairs by two surgeons working on two different fingers with two microscopes to save time (Figure 29).

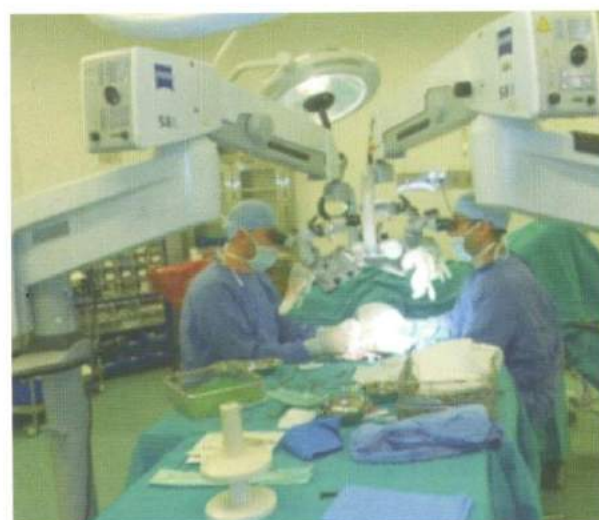

Figure 29: Two surgeons repairing different fingers simultaneously by two microscopes in a multi-finger distal replantation.

REFERENCES

1. Foucher G, Norris RW. Distal and very distal digital replantations. *Br J Plast Surg* 1992;45(3):199-203.
2. Morrison WA, McCombe D. Digital replantation. *Hand Clin* 2007;23:1-12.
3. Goldner RD, Stevanovic MV, Nunley JA, Urbaniak JR. Digital replantation at the level of the distal interphalangeal joint and the distal phalanx. *J Hand Surg [Am]* 1989;14:214-220.
4. Hattori Y, Doi K, Ikeda K, Estrella EP. A retrospective study of functional outcomes after successful replantation versus amputation closure for single fingertip amputations. *J Hand Surg* 2006;31A:811-818.
5. Strauch B, de Moura W. Arterial system of the fingers. *J Hand Surg* 1990;15A:148-154.
6. Smith DO, Oura C, Kimura C, Toshimori K. The distal venous anatomy of the finger. *J Hand Surg* 1991;16A:303-307.
7. Grabb and Smith Plastic Surgery. 3rd Edn. Boston, Little, Brown, 1979: 701.
8. Blackburn AV, Jemec B. The microsurgical instrument tray - a tremor-free assistant for stabilising amputated parts in replant surgery. *J Plast Reconstr Aesthet Surg*. 2007;60(8):961
9. Venkatramani H, Sabapathy SR. A simple technique for securing the amputated part during preparation in fingertip replantation. *Br J Plast Surg* 2004;57:592-3.
10. Kabakas F, Ugurlar M, Yigit B, Purisa H. Tissue forceps for stabilizing amputated parts in a finger replantation. *Hand and Microsurgery*. 2016;5(3):178-179
11. Ozcelik IB, Tuncer S, Purisa H, Sezer I, Mersa B, Kabakas F, Celikdelen P. Sensory outcome of fingertip replantations without nerve repair. *Microsurgery* 2008;28:524-530.
12. Faivre S, Lim A, Dautel G, Duteille F, Merle M. Adjacent and spontaneous neurotization after distal digital replantation in children. *Plast Reconstr Surg* 2003;111:159-165
13. Wong C, Ho PC, Tse WL, Cheng S, Chan DK, Hung LK. Do we need to repair the nerves when replanting distal finger amputations? *J Reconstr Microsurg* 2010;26:347-354.
14. Kabakas F. Dorsal approach for vascular repairs in distal finger replantations. *Microsurgery*. 2016 Nov;36(8):628-636
15. Mersa B, Kabakas F, Purisa H, Ozcelik IB, Yesiloglu N, Sezer I, Tunçer S. Advantages of using volar vein repair in finger replantations. *J Plast Reconstr Aesthet Surg*. 2014 Jan;67(1):63-7